

CLINICAL REPORT

Implant overdentures retained by self-aligning stud-type attachments: A clinical report

Murali Srinivasan, PD, Dr med dent, BDS, MDS, MBA, MAS,^a Nicole Kalberer, Med dent, MAS,^b Sabrina Maniewicz, Med dent, MAS,^c and Frauke Müller, Dr med dent habil^d

Removable prostheses retained by dental implants are successful treatment options with high patient satisfaction, improved comfort, prosthesis stability, and masticatory function compared with conventional dentures.¹⁻¹⁴ Implant overdentures (IODs) retained by 2 implants significantly improve the Oral Health-Related Quality of Life (OHRQoL) of elderly edentulous patients.^{10,15-23} The success of IODs and implant-retained removable partial dentures (RPDs) depends on the performance of the attachment system.²⁴

Splinted anchorage systems, such as bar attachments, are highly retentive with a fairly low long-term maintenance requirement.²⁵⁻²⁸ However, they have a high initial cost; are difficult to fabricate; and may be complicated to repair, modify, or remake.^{29,30} In contrast, the unsplinted stud anchorage systems such as the spherical anchor or the LOCATOR attachment (Zest IP Holdings, LLC) are straightforward to process and have a low initial cost.³⁰⁻³² Although the LOCATOR attachment is the most widely used attachment for IODs,³³ it has been criticized as being difficult for dependent elders to use.³⁴ In addition, these attachments are prone to wear and rapid loss of retention and require periodic maintenance visits.³⁵⁻³⁸

A recently introduced attachment (LOCATOR R-Tx Removable Attachment System; Zest IP Holdings, LLC)

ABSTRACT

The functionality of a new overdenture attachment (LOCATOR R-Tx) was described for different clinical situations: a conventional mandibular implant overdenture (IOD) retained by 2 implants, a straightforward chairside maintenance procedure for replacing a worn LOCATOR (Legacy) attachment with the new LOCATOR R-Tx, and a complex clinical situation with nonideal implant positions with compromised parallelism. The LOCATOR R-Tx is an advance on the existing LOCATOR Legacy attachment and has an improved abutment head design with a more durable surface coating to prevent attachment wear and thereby reduce frequency of maintenance. (J Prosthet Dent 2019;■:■-■)

overcame some of these drawbacks. The abutment design is intended to provide the same clinical handling as the earlier design but with the benefits of a narrower coronal geometry, an improved surface coating, and greater flexibility in terms of the interimplant angular compensatory mechanism. The purpose of this clinical report was to document the versatility and the ease of use of the new LOCATOR R-Tx attachment in 3 different clinical situations.

Clinical indication #1: mandibular IOD retained by 2 tissue-level implants

A 74-year-old woman was referred for the rehabilitation of her completely edentulous maxilla and mandible. Her chief complaints included inability to eat properly and poor esthetics. Her maximum mouth opening was normal with no evidence of TMJ problems and no history of parafunctional habits. Intraoral and radiographic

^aPrivat-docent, Division of Gerodontology and Removable Prosthodontics, University Clinics of Dental Medicine, University of Geneva, Geneva, Switzerland; Professor and Head, Clinic for General, Special care, and Geriatric Dentistry, Center of Dental Medicine, University of Zurich, Zurich, Switzerland.

^bResearch and Teaching Assistant, Division of Gerodontology and Removable Prosthodontics, University Clinics of Dental Medicine, University of Geneva, Geneva, Switzerland.

^cResearch and Teaching Assistant, Division of Gerodontology and Removable Prosthodontics, University Clinics of Dental Medicine, University of Geneva, Geneva, Switzerland.

^dProfessor and Chair, Division of Gerodontology and Removable Prosthodontics, University Clinics of Dental Medicine, University of Geneva, Geneva, Switzerland; Professor, Service of Geriatrics, Department of Internal Medicine, Rehabilitation and Geriatrics, University Hospitals of Geneva, Thônex, Switzerland.

examinations revealed a moderately resorbed edentulous maxilla and a more severely resorbed mandible. The treatment planned was to rehabilitate the edentulous jaws with a conventional maxillary complete denture (CD) opposing an implant-retained mandibular IOD (Fig. 1A, B).

The prostheses were fabricated following a 3-visit digital denture protocol,³⁹ and the patient was first provided with interim trial dentures (AvaDent Digital Dental Solutions Europe; Global Dental Science Europe BV). The trial dentures were worn for a period of 1 month, enabling modifications to be made and allowing the patient to adapt to the new prostheses. Once the patient was accustomed to and comfortable with the trial dentures, implant surgery was planned. By using the mandibular trial denture as a surgical guide, 2 implants (4.1 mm in diameter and 10 mm in length, Regular Neck Tissue Level; Institut Straumann AG) were placed in a single-stage surgery in the mandibular canine region following a standard surgical protocol. After surgery, the mandibular trial denture was relieved sufficiently to not contact the implants and was relined by using a functional impression tissue conditioning material (F.I.T.T.; Kerr Corp). After a healing period of 6 weeks, definitive reline impressions were made by using the trial dentures. The impressions were then scanned and sent to the digital denture manufacturer. The digital dental laboratory incorporated the second set of definitive impressions into the existing denture design and fabricated a set of computer-aided design and computer-aided manufacture (CAD-CAM) fully milled maxillary and mandibular dentures (AvaDent; Global Dental Science Europe BV). The mandibular IOD was milled to include the spaces to accommodate the matrices to be processed intraorally. The definitive CAD-CAM milled dentures were clinically evaluated for retention, stability, fit, extensions, esthetics, and occlusion.

The healing abutments were removed, and the height of the peri-implant gingival cuff was measured by using the abutments (LOCATOR PLAN; Institut Straumann AG) (Fig. 1C). The gingival cuff height was 2 mm, and the appropriate abutments (LOCATOR R-Tx tissue level RP; Zest IP Holdings, LLC), were selected (Fig. 2A, B). The abutments were first hand-tightened on the implants by using a standard hexagonal driver (Zest IP Holdings, LLC) and then tightened to 30 Ncm by using a calibrated torque wrench (Zest IP Holdings, LLC) following the manufacturer's instructions (Fig. 2C). The white block-out spacers (Zest IP Holdings, LLC) were then placed on the LOCATOR R-Tx abutments, and the matrices with the black processing inserts were snapped onto each abutment (Fig. 3A). The mandibular denture was then evaluated and adjusted for clearance guided by a silicone material (Fit Checker Advanced; GC Corp) (Fig. 3B). The denture was then

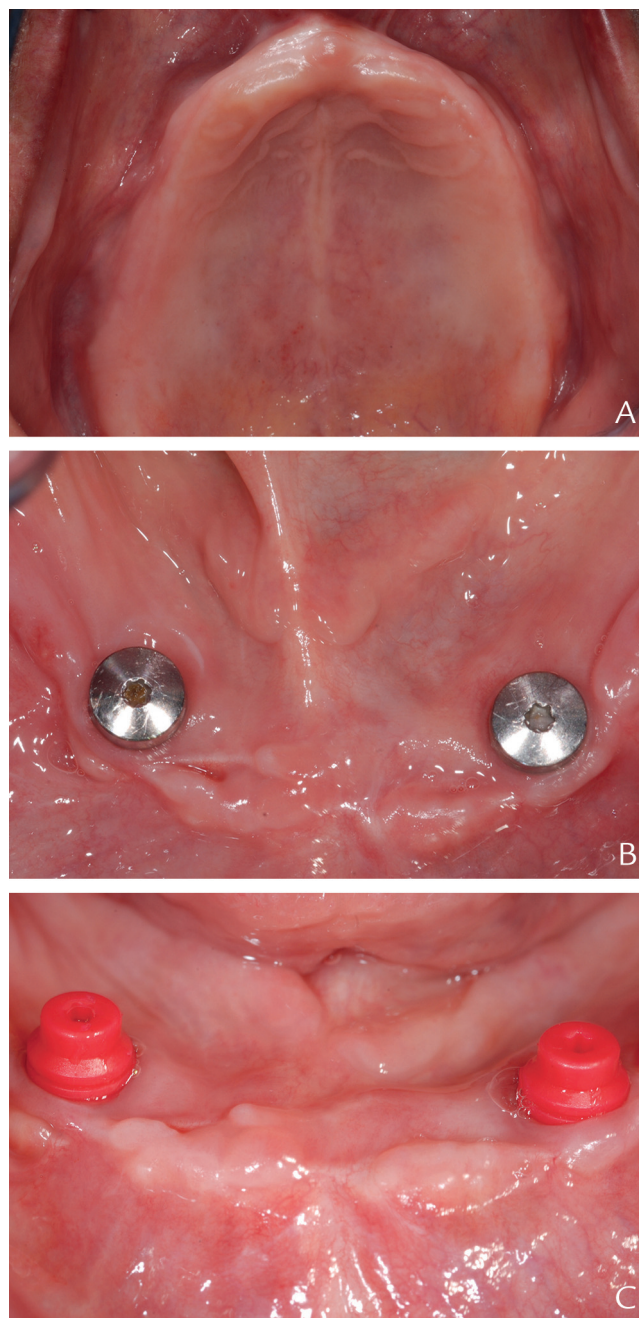


Figure 1. Patient #1 initial situation and abutment selection. A, Intraoral view of edentulous maxilla. B, Intraoral view of edentulous mandible with 2 tissue-level implants ready for loading. C, LOCATOR PLAN abutments in place showing 2-mm gingival cuff height.

cleaned and prepared for the intraoral processing of the matrices. Petroleum jelly (Vaseline; Unilever) was applied on the mucosa of the edentulous ridge adjacent to the implants and on the lips to prevent irritation from the autopolymerizing polymethylmethacrylate (PMMA) resin. Care was taken not to contaminate the matrices with the petroleum jelly. The PMMA resin (Unifast; GC Europe N.V.) was mixed and applied on top of the

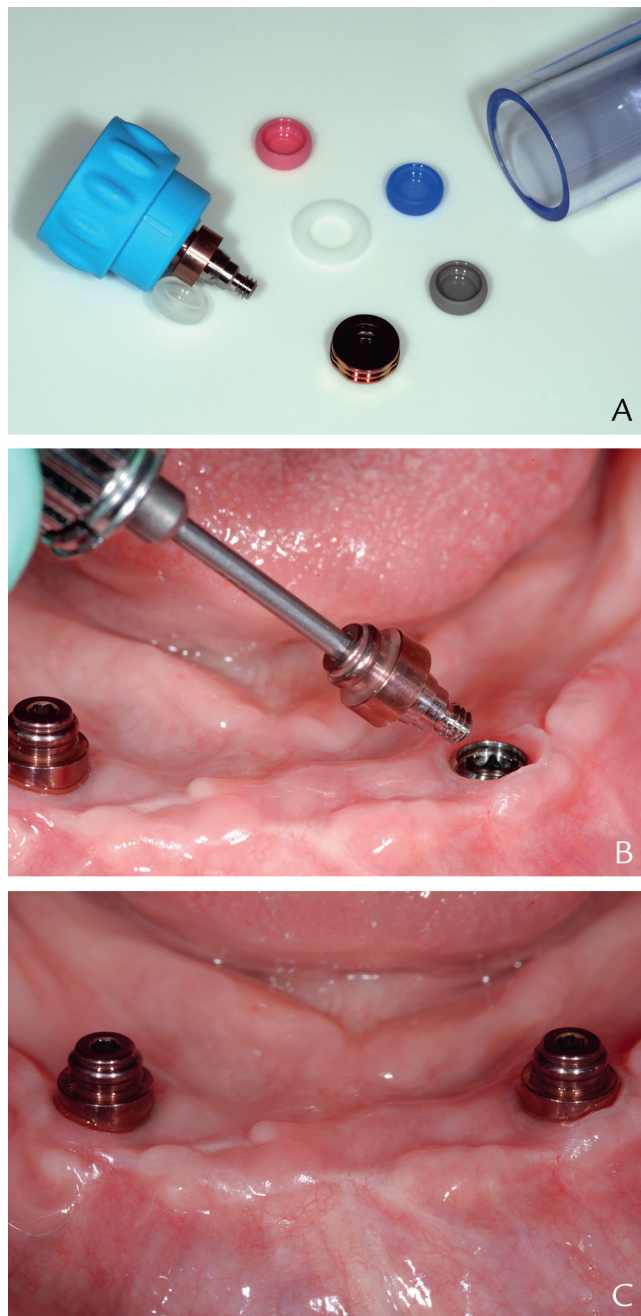


Figure 2. Positioning of LOCATOR R-Tx abutments. A, LOCATOR R-Tx abutment, matrices, and retentive inserts. B, Abutment being positioned and tightened. C, Attachments ready for denture processing.

matrices and into the milled housing spaces of the mandibular denture by using a microbrush (3M ESPE) (Fig. 3C). The mandibular denture was then inserted, and the patient was requested to occlude into centric occlusion until the PMMA resin had polymerized (Fig. 4A). The denture was then removed and inspected. Excess resin around the matrices was trimmed and finished. The black processing inserts were replaced with definitive gray (zero) retention inserts (Fig. 4B).

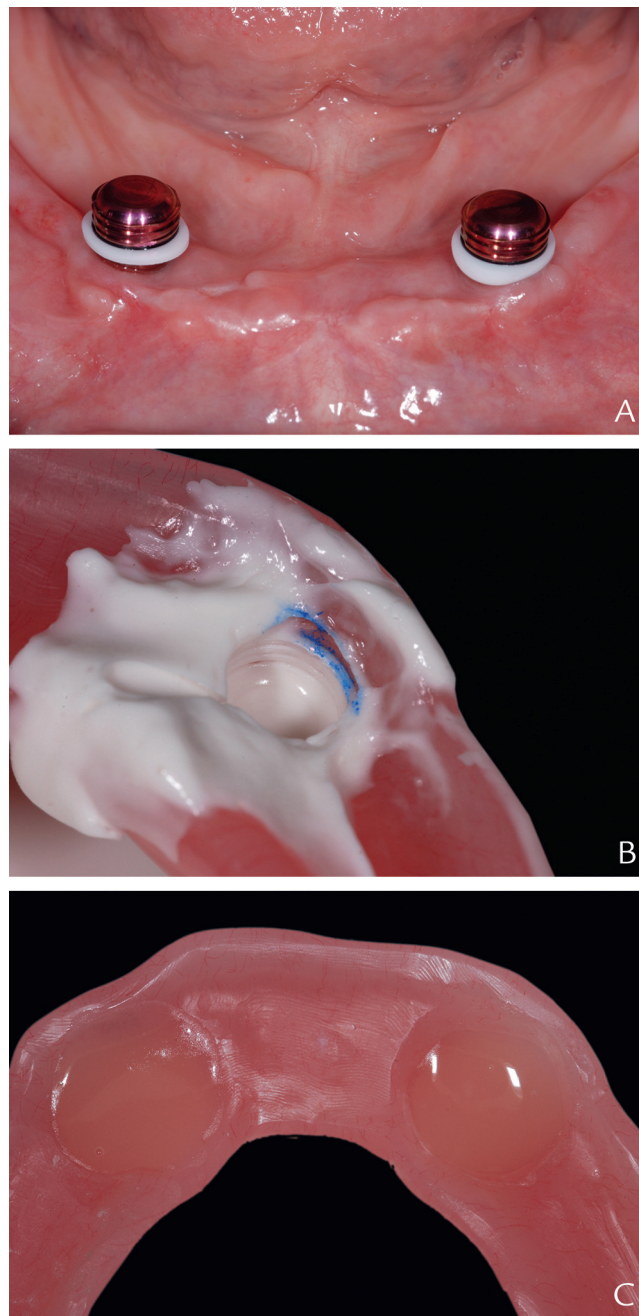


Figure 3. Space verification. A, White block-out spacers and matrices positioned. B, Silicone material verifying available space. C, Autopolymerizing PMMA resin placed in housing space. PMMA, polymethylmethacrylate.

Finally, postinsertion and denture hygiene instructions were given to the patient (Fig. 4C).

Indication #2: replacement of a worn out LOCATOR Legacy attachment in a cast RPD

A 67-year-old woman with a cast RPD retained by implants presented with the complaint of loss of retention in her RPD. An intraoral examination revealed that the

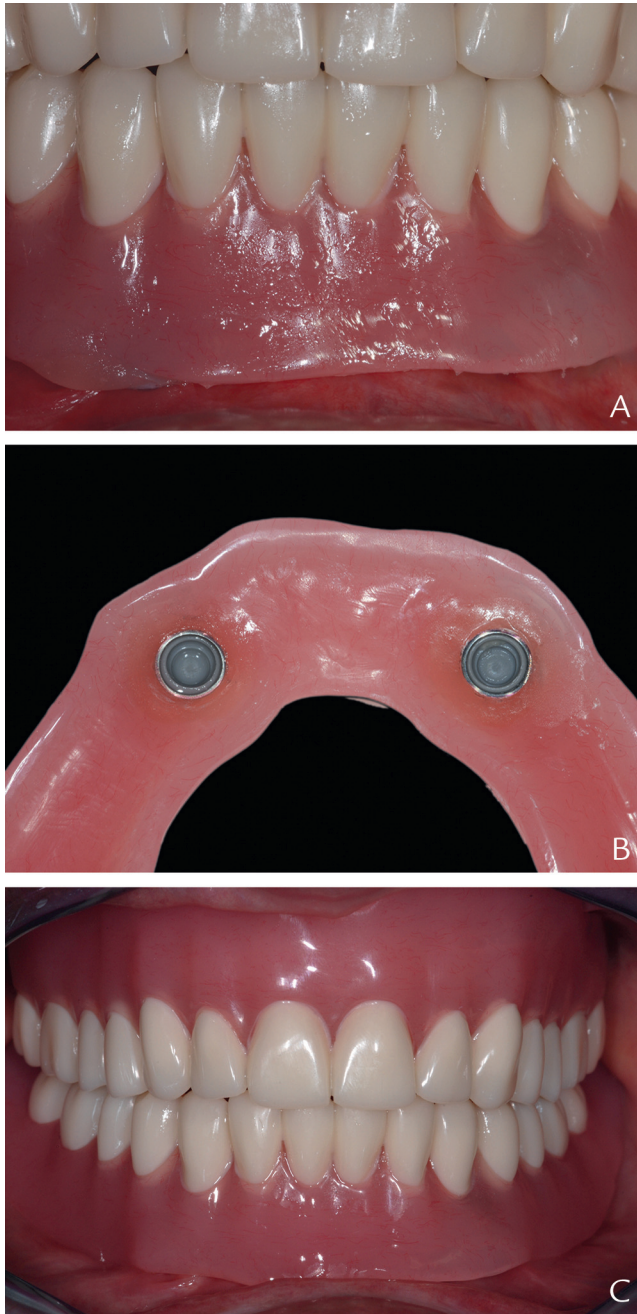


Figure 4. Matrix processing and definitive result. A, Denture positioned on abutments and patient occluding in centric occlusion. B, Gray (zero) retentive inserts placed after finishing and polishing of processed denture. C, Processed denture in situ.

patient had a Kennedy Class I partially edentulous maxilla with few remaining anterior teeth opposing a restored natural dentition (Fig. 5A). Two implants (Regular Neck Tissue Level; Institut Straumann AG) were present in the maxilla's first premolar regions with LOCATOR Legacy attachments (Fig. 5B). The attachments had been in situ for 9 years and presented with severe wear (Fig. 5C). The treatment plan was to replace

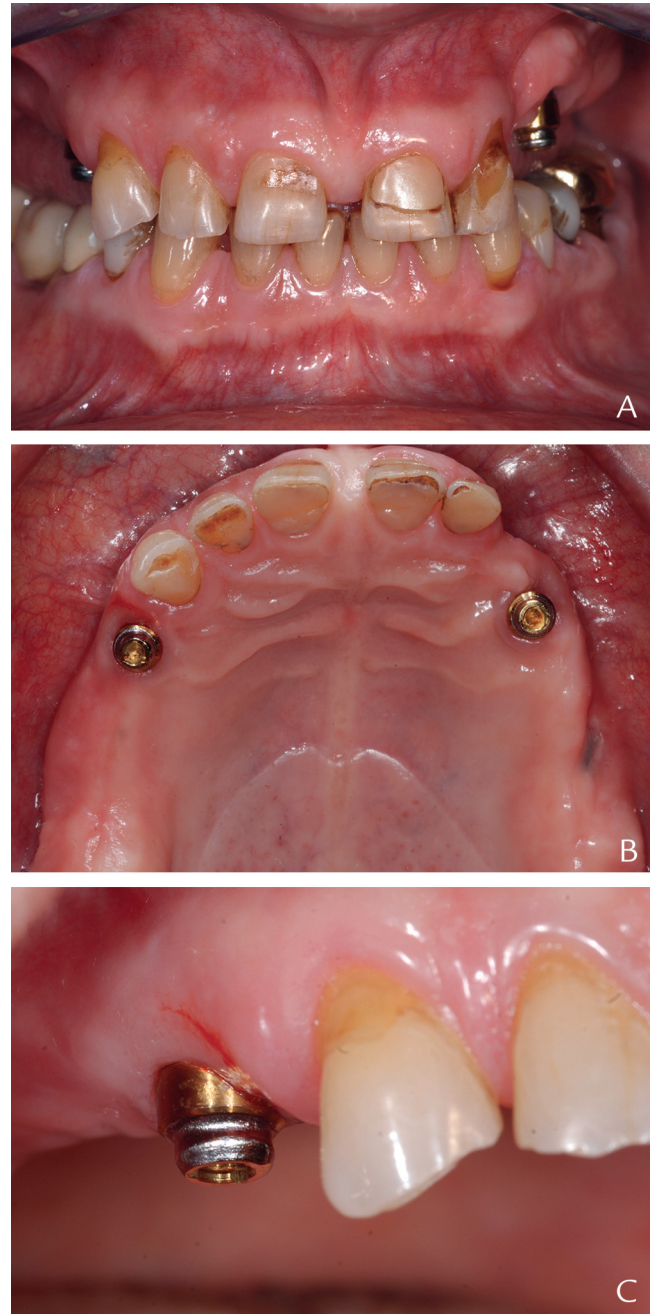


Figure 5. Patient #2 initial situation. A, Intraoral view of initial situation. B, Occlusal view showing Kennedy class I partially edentulous maxilla with implants and LOCATOR Legacy abutments. C, Existing worn LOCATOR Legacy abutments.

the existing attachments with LOCATOR R-Tx tissue level RP abutments and change the corresponding matrices intraorally in the same visit. The existing LOCATOR abutments were first removed, and the height of the new LOCATOR R-Tx abutment to be used was confirmed with the PLAN abutments (Fig. 6A). The 2-mm-high LOCATOR R-Tx abutments were selected, hand-tightened on the implants, and then tightened to

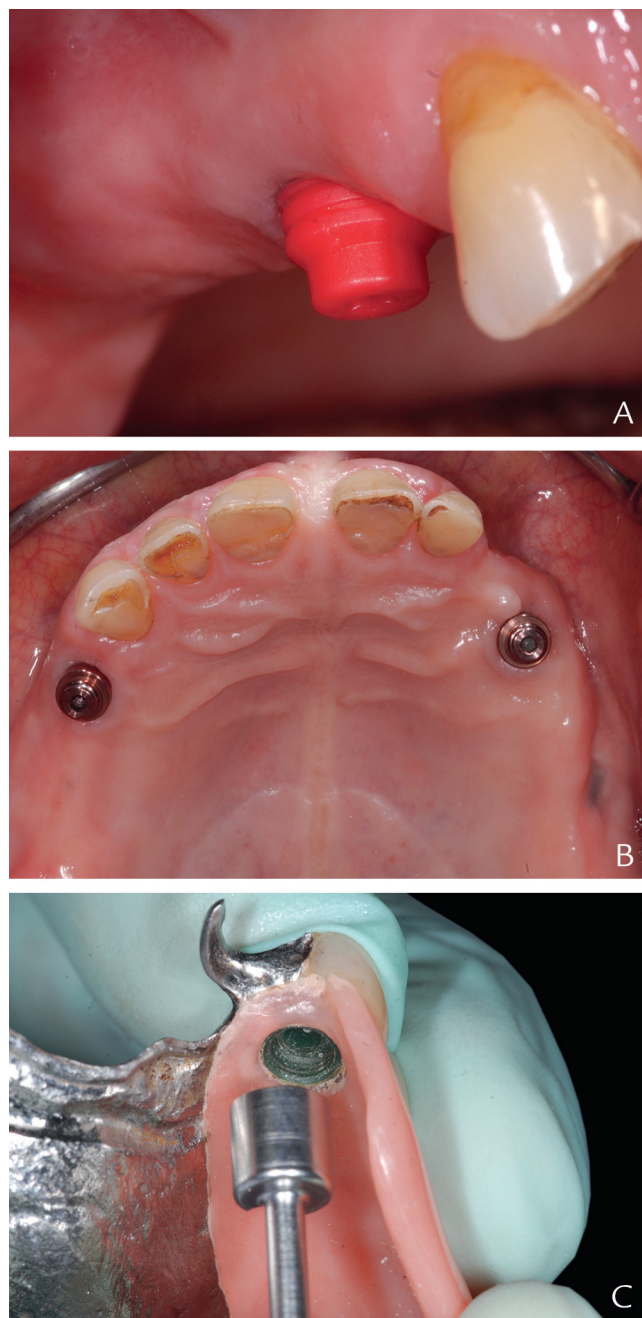


Figure 6. Abutment height selection, abutment positioning, and denture preparation. A, PLAN abutment in place. B, Selected LOCATOR R-Tx abutment ready for RPD processing. C, Matrices being removed by using housing extractor. RPD, removable partial denture.

30 Ncm as recommended by the manufacturer (Fig. 6B). The existing matrices were then extracted from the RPD by using a housing extractor (Cendres+Métaux SA) (Fig. 6C). The white block-out spacer was placed on the LOCATOR R-Tx abutments, and the new matrices were snapped onto the abutments (Fig. 7A). Intraoral processing of the matrices into the RPD was performed as described previously (Fig. 7B). The patient was satisfied with the retention and the overall result (Fig. 7C).

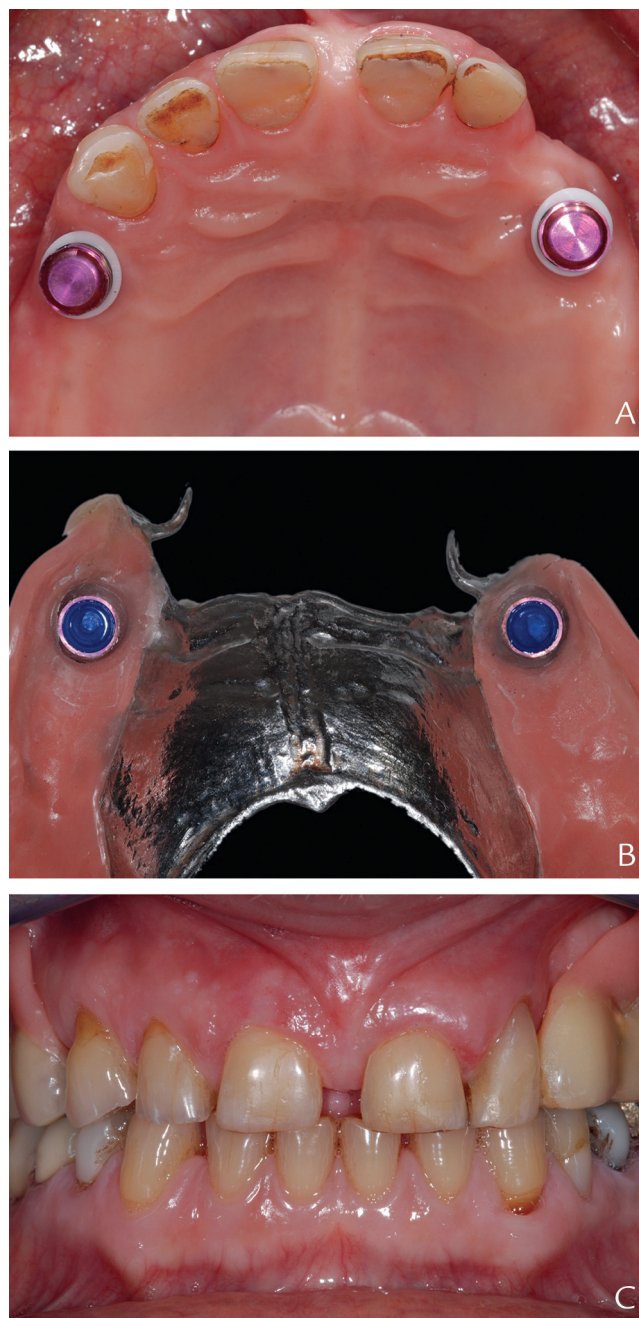


Figure 7. Matrix processing and definitive result. A, Block-out spacer and matrices placed on abutments. B, Processed RPD with definitive inserts in place ready for insertion. C, Definitive result. RPD, removable partial denture.

Indication #3: rehabilitation of maxillary and mandibular edentulous arches with IODs

A 50-year-old woman with compromised general health was referred for a presurgical dental evaluation to exclude oral infection. Her medical history revealed that she was a multimorbid patient with a level 5 (medium) dependency according to the CSHA (Canadian Scale of Health and Aging). She was hospitalized because of

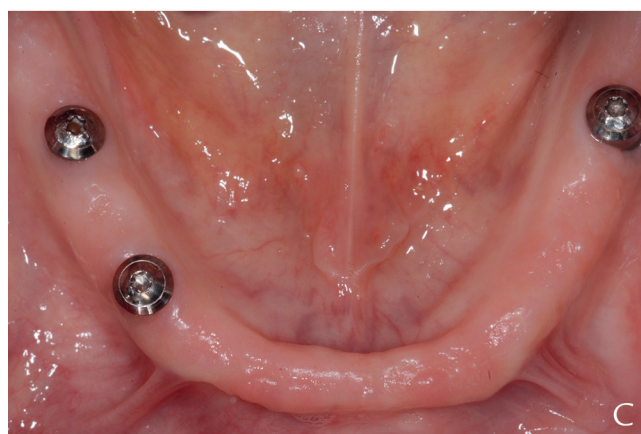
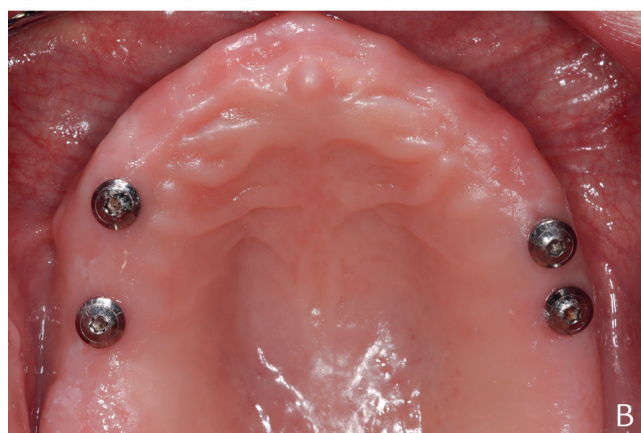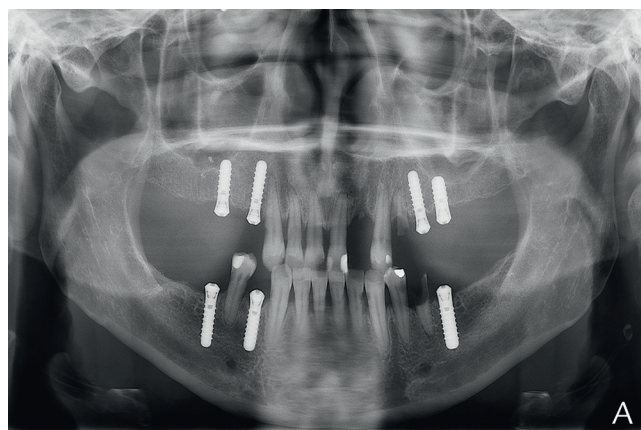


Figure 8. Patient #3 initial situation. A, Panoramic radiographs. B and C, Intraoral view of edentulous maxilla and mandible with implants in situ.

complications of diabetic ketosis after a disconnected insulin pump. She was scheduled to receive a pancreatic graft. Intraoral and radiographic examination showed a failing dentition with advanced periodontitis, multiple untreated extensive carious lesions, and 7 unrestored implants (Regular Neck Tissue Level; Institut Straumann AG) that had been in situ for 14 years (Fig. 8A). The patient's chief wish was to have a functional dentition and be able to bite into an apple. After discussions, the decision was made to extract all the remaining teeth and

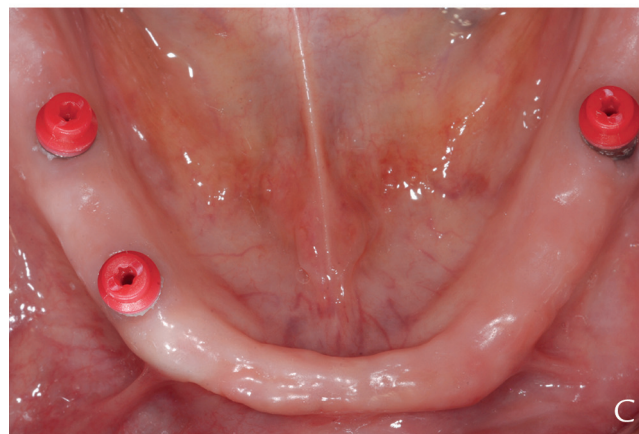
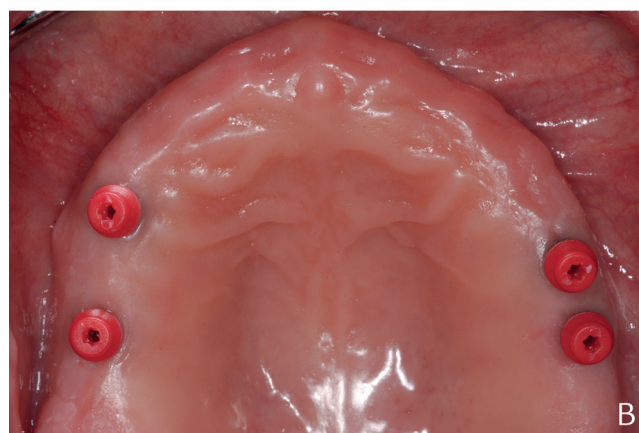
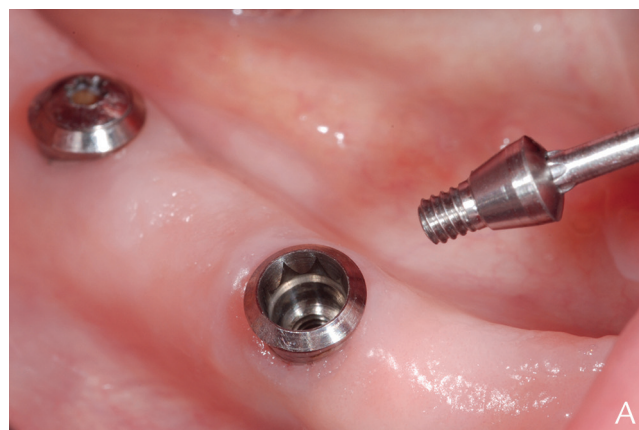

Figure 9. Selecting attachment height. A, Cover-screw being removed. B and C, PLAN abutments in place.

use the existing implants to rehabilitate the jaws with IODs. The remaining teeth were extracted, and immediate maxillary and mandibular CDs were delivered.

A detailed intraoral examination after healing revealed that the implants were not parallel and were not in ideal positions. In the maxilla, the 4 implants were present in the tooth positions of the right first molar and first premolar and the left first molar and second premolar (Fig. 8B). In the mandible, there were 3 implants in the tooth positions of the left first molar, right first molar,

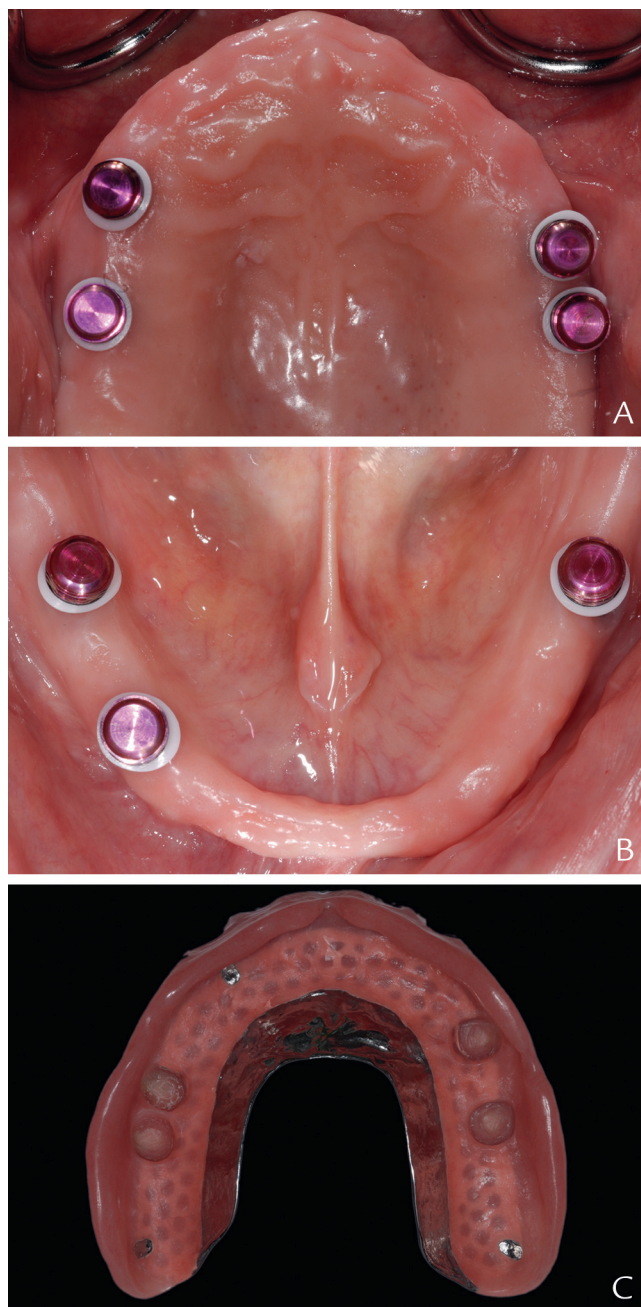


Figure 10. Matrix processing. A and B, Intraoral occlusal views showing selected LOCATOR R-Tx abutments with block-out spacers and matrices. C, IOD ready for incorporating matrices. IOD, implant-supported overdenture.

and first premolar (Fig. 8C). The implants were originally placed to provide single crowns and an implant-supported fixed partial denture; however, because of medical and other reasons, the patient was not able to have her implants restored. Inserting additional implants was not possible for medical and financial reasons. The decision to use LOCATOR R-Tx abutments was made as they can compensate for interimplant angular discrepancies up to 60 degrees. All conventional denture fabrication steps

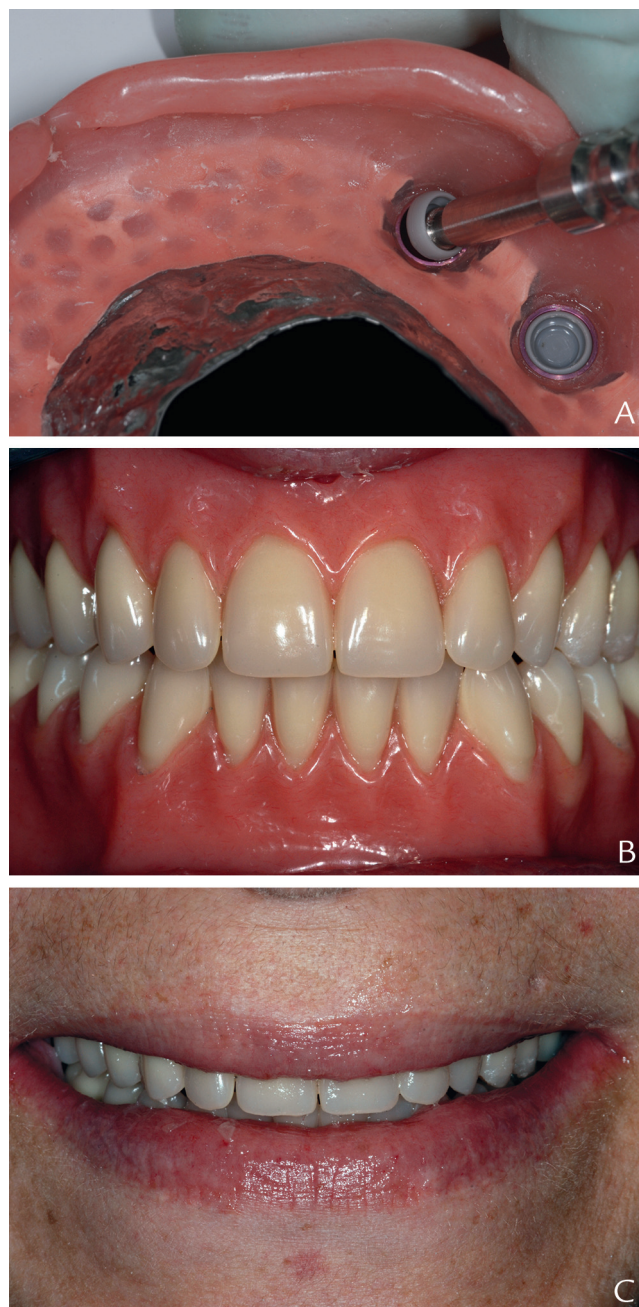

Figure 11. Definitive result. A, Gray (zero) definitive inserts being placed. B and C, Processed overdentures in situ.

were followed, and IODs with metal reinforcements were fabricated. The matrices were attached intraorally following the protocol described previously (Figs. 9-11). The patient was satisfied with the esthetic and functional outcome of her IODs (Fig. 11C).

DISCUSSION

This clinical report describes the rehabilitation of partially and completely edentulous patients with IODs by using a

recently introduced attachment system. The LOCATOR R-Tx attachment is a replacement for the existing LOCATOR (now called “LOCATOR Legacy”), alleviating the drawbacks of the former. The LOCATOR R-Tx design has eliminated the central channel present on the attachment head of the classic LOCATOR Legacy. This has now been replaced with an industry standard hexagon that greatly reduces the central space and may avoid being a nidus for entrapment of debris and biofilm accumulation. The shape of the head has been redesigned with a dual-retentive surface with a narrower and more pyramid-shaped coronal geometry that allows an angular compensation of up to 60 degrees between implants. A design modification is the improved titanium carbon nitride coating (DuraTec coating; Zest IP Holdings LLC) to prevent surface wear. This surface has yet to be validated in terms of manufacturer-independent *in vitro* and clinical testing, but the new surface should be an improvement over the former as frequent wear and loss of retention has been a problem for the classic LOCATOR.³⁸ The new pink color might be favorable when thin layers of denture resin cover the attachment and blends into the surrounding oral mucosa.

When an attachment has been phased out and replaced, it is often a problem updating the existing attachment without changing the prostheses. Problems such as prosthetic space, clinical indications, and retentive mechanisms might complicate the change, add to the cost, and necessitate multiple patient visits. The LOCATOR R-Tx can be easily incorporated into any functional prostheses formerly retained by the LOCATOR Legacy attachment. Moreover, the change requires a straightforward chairside procedure with minimal instrumentation.

The LOCATOR R-Tx allows for up to 60 degrees of angular compensation between implants. This is a clinical advantage as this can successfully be implemented in clinical situations with considerable interimplant angular discrepancies. The attachment does not require different abutments or other mechanisms to provide this compensation. How this feature might affect the retentive potential over time and/or the wear of the attachment; these need to be validated by *in vitro* and/or clinical testing.

SUMMARY

The LOCATOR R-Tx abutment is a replacement for the former LOCATOR “Legacy” attachment, presenting with an improved design and a seemingly more durable surface coating. The extended flexibility of the LOCATOR R-Tx’s angular compensatory mechanism between implants could be of benefit in clinically challenging situations. The ease of use in terms of its clinical manipulation makes this an attachment suitable for treating elderly or compromised patients. Clinical studies are needed to assess its maintenance requirements, which is expected

to be lower because of its enhanced attachment geometry and surface coating.

REFERENCES

- Bural C, Buzbas B, Ozatik S, Bayraktar G, Emes Y. Distal extension mandibular removable partial denture with implant support. *Eur J Dent* 2016;10:566-70.
- Mitrani R, Brudvik JS, Phillips KM. Posterior implants for distal extension removable prostheses: a retrospective study. *Int J Periodontics Restorative Dent* 2003;23:353-9.
- Wismeijer D, Tawse-Smith A, Payne AG. Multicentre prospective evaluation of implant-assisted mandibular bilateral distal extension removable partial dentures: patient satisfaction. *Clin Oral Implants Res* 2013;24:20-7.
- Bortolini S, Natali A, Franchi M, Coggiola A, Consolo U. Implant-retained removable partial dentures: an 8-year retrospective study. *J Prosthodont* 2011;20:168-72.
- de Freitas RF, de Carvalho Dias K, da Fonte Porto Carreiro A, Barbosa GA, Ferreira MA. Mandibular implant-supported removable partial denture with distal extension: a systematic review. *J Oral Rehabil* 2012;39:791-8.
- El Mekawy NH, El-Negoly SA, Grawish Mel A, El-Hawary YM. Intraoral mandibular Kennedy class I implant-tooth supported removable partial overdenture: a 2-year multicenter prospective study. *Int J Oral Maxillofac Implants* 2012;27:677-83.
- Ohkubo C, Kobayashi M, Suzuki Y, Hosoi T. Effect of implant support on distal-extension removable partial dentures: *in vivo* assessment. *Int J Oral Maxillofac Implants* 2008;23:1095-101.
- Fontijn-Tekamp FA, Slagter AP, Van Der Bilt A, Van 'T Hof MA, Witter DJ, Kalk W, et al. Biting and chewing in overdentures, full dentures, and natural dentitions. *J Dent Res* 2000;79:1519-24.
- Kremer U, Schindler S, Enkling N, Worni A, Katsoulis J, Mericske-Stern R. Bone resorption in different parts of the mandible in patients restored with an implant overdenture. A retrospective radiographic analysis. *Clin Oral Implants Res* 2016;27:267-72.
- Müller F, Duvernay E, Loup A, Vazquez L, Herrmann FR, Schimmel M. Implant-supported mandibular overdentures in very old adults: a randomized controlled trial. *J Dent Res* 2013;92:154S-60S.
- Awad MA, Lund JP, Shapiro SH, Locker D, Klemetti E, Chehade A, et al. Oral health status and treatment satisfaction with mandibular implant overdentures and conventional dentures: a randomized clinical trial in a senior population. *Int J Prosthodont* 2003;16:390-6.
- Raghoebar GM, Meijer HJ, Stegenga B, van't Hof MA, van Oort RP, Vissink A. Effectiveness of three treatment modalities for the edentulous mandible. A five-year randomized clinical trial. *Clin Oral Implants Res* 2000;11:195-201.
- Timmerman R, Stoker GT, Wismeijer D, Oosterveld P, Vermeeren JJ, van Waas MA. An eight-year follow-up to a randomized clinical trial of participant satisfaction with three types of mandibular implant-retained overdentures. *J Dent Res* 2004;83:630-3.
- Meijer HJ, Raghoebar GM, Batenburg RH, Visser A, Vissink A. Mandibular overdentures supported by two or four endosseous implants: a 10-year clinical trial. *Clin Oral Implants Res* 2009;20:722-8.
- van der Bilt A, Burgers M, van Kampen FM, Cune MS. Mandibular implant-supported overdentures and oral function. *Clin Oral Implants Res* 2010;21:1209-13.
- van Kampen FM, van der Bilt A, Cune MS, Fontijn-Tekamp FA, Bosman F. Masticatory function with implant-supported overdentures. *J Dent Res* 2004;83:708-11.
- Feine JS, Carlsson GE, Awad MA, Chehade A, Duncan WJ, Gizani S, et al. The McGill consensus statement on overdentures. Mandibular two-implant overdentures as first choice standard of care for edentulous patients. Montreal, Quebec, May 24-25, 2002. *Int J Oral Maxillofac Implants* 2002;17:601-2.
- Thomason JM, Feine J, Exley C, Moynihan P, Müller F, Naert I, et al. Mandibular two implant-supported overdentures as the first choice standard of care for edentulous patients—the York Consensus Statement. *Br Dent J* 2009;207:185-6.
- Thomason JM, Kelly SA, Bendkowski A, Ellis JS. Two implant retained overdentures—a review of the literature supporting the McGill and York consensus statements. *J Dent* 2012;40:22-34.
- Thomason JM, Lund JP, Chehade A, Feine JS. Patient satisfaction with mandibular implant overdentures and conventional dentures 6 months after delivery. *Int J Prosthodont* 2003;16:467-73.
- Awad MA, Rashid F, Feine JS. Overdenture Effectiveness Study Team C. The effect of mandibular 2-implant overdentures on oral health-related quality of life: an international multicentre study. *Clin Oral Implants Res* 2014;25:46-51.
- Emami E, Heydecke G, Rompre PH, de Grandmont P, Feine JS. Impact of implant support for mandibular dentures on satisfaction, oral and general health-related quality of life: a meta-analysis of randomized-controlled trials. *Clin Oral Implants Res* 2009;20:533-44.

23. Rashid F, Awad MA, Thomason JM, Piovano A, Spielberg GP, Scilingo E, et al. The effectiveness of 2-implant overdentures - a pragmatic international multicentre study. *J Oral Rehabil* 2011;38:176-84.
24. Rutkunas V, Mizutani H, Takahashi H, Iwasaki N. Wear simulation effects on overdenture stud attachments. *Dent Mater J* 2011;30:845-53.
25. Walton JN, MacEntee MI, Glick N. One-year prosthetic outcomes with implant overdentures: a randomized clinical trial. *Int J Oral Maxillofac Implants* 2002;17:391-8.
26. van Kampen F, Cune M, van der Bilt A, Bosman F. Retention and post-insertion maintenance of bar-clip, ball and magnet attachments in mandibular implant overdenture treatment: an in vivo comparison after 3 months of function. *Clin Oral Implants Res* 2003;14:720-6.
27. MacEntee M. Mandibular overdentures retained by a bar on two implants need less aftercare and costs less than overdentures retained by two bars on three implants or by ball attachments on two implants. *J Evid Based Dent Pract* 2008;8:76-7.
28. Stoker GT, Wismeijer D, van Waas MA. An eight-year follow-up to a randomized clinical trial of aftercare and cost-analysis with three types of mandibular implant-retained overdentures. *J Dent Res* 2007;86:276-80.
29. Gottfredsen K, Holm B. Implant-supported mandibular overdentures retained with ball or bar attachments: a randomized prospective 5-year study. *Int J Prosthodont* 2000;13:125-30.
30. Steffen RP, White V, Markowitz NR. The use of ballclip attachments with an implant-supported primary-secondary bar overdenture. *J Oral Implantol* 2004;30:234-9.
31. Davis DM, Packer ME. Mandibular overdentures stabilized by Astra Tech implants with either ball attachments or magnets: 5-year results. *Int J Prosthodont* 1999;12:222-9.
32. Krennmair G, Seemann R, Weinlander M, Piehslinger E. Comparison of ball and telescopic crown attachments in implant-retained mandibular overdentures: a 5-year prospective study. *Int J Oral Maxillofac Implants* 2011;26:598-606.
33. Kronstrom M, Carlsson GE. An international survey among prosthodontists of the use of mandibular implant-supported dental prostheses. *J Prosthodont* 2019;28:e622-6.
34. Mackie A, Lyons K, Thomson WM, Payne AG. Mandibular two-implant overdentures: three-year prosthodontic maintenance using the Locator attachment system. *Int J Prosthodont* 2011;24:328-31.
35. Alsabeeha N, Atieh M, Swain MV, Payne AG. Attachment systems for mandibular single-implant overdentures: an in vitro retention force investigation on different designs. *Int J Prosthodont* 2010;23:160-6.
36. Kleis WK, Kämmerer PW, Hartmann S, Al-Nawas B, Wagner W. A comparison of three different attachment systems for mandibular two-implant overdentures: one-year report. *Clin Implant Dent Relat Res* 2010;12:209-18.
37. Abi Nader S, de Souza RF, Fortin D, De Koninck L, Fromentin O, Albuquerque RF. Effect of simulated masticatory loading on the retention of stud attachments for implant overdentures. *J Oral Rehabil* 2011;38:157-64.
38. Guedat C, Nagy U, Schimmel M, Muller F, Srinivasan M. Clinical performance of LOCATOR(R) attachments: A retrospective study with 1-8 years of follow-up. *Clin Exp Dent Res* 2018;4:132-45.
39. Srinivasan M, Kalberer N, Naharro M, Marchand L, Lee HJ, Müller F. CAD-CAM milled dentures: the Geneva protocols for digital-dentures. Accepted for publication in the *Journal of Prosthetic Dentistry* on 2 January 2019 (Manuscript ID: JPD-D-18-00723).

Corresponding author:

Dr Frauke Müller
Division of Gerodontology and Removable Prosthodontics
1, Rue Michel-Servet
1211 Geneva-4
SWITZERLAND
Email: frauke.mueller@unige.ch

Acknowledgments

The authors thank Zest IP Holdings, LLC, for the provision of the overdenture attachment components free of charge to help complete the cases. No other source of external funding was received for the completion of these clinical reports, and the authors wish to declare that they have no conflicts of interests. The authors would like to acknowledge Ms Manasa Kumar and Mrs Marie-Ange Genet, final year predoctoral students, along with Ms Sybille Chatelain who works as a research and teaching assistant in the Department of Oral Surgery and Implantology, Geneva University Hospitals, Geneva, Switzerland, for their valuable contribution toward the successful completion of the illustrated treatments.

Copyright © 2019 by the Editorial Council for *The Journal of Prosthetic Dentistry*.
<https://doi.org/10.1016/j.prosdent.2019.03.009>