

An affordable overdenture option for an edentulous ridge

Dr. Ara Nazarian discusses the benefits of a small diameter implant

As the Baby Boomer population increases in number and size, so does the number of edentulous patients, since tooth loss and age are totally related. Whether it is due to neglect, caries, medications, or other systemic reasons, patients are presenting to practices all over America with their teeth already extracted.

However, patients who have been wearing removable prosthetics for several years may discover the common denture problems of instability, sores, and pain. Their dentures no longer fit very well, unless they incorporate some type of implants into the plan. Implants, whether small or traditional, allow patients with dentures to eat and function like they once did when they had teeth.

Endosseous implants have been successfully used to restore edentulous ridges with implant-supported fixed bridges, hybrid prosthetic dentures, and removable overdenture prostheses for many years. However, due to deficiencies in the remaining bone, complicated medical history, or financial reasons, not everyone is a candidate for traditional-sized implants.

Small diameter implants placed with flapless surgery to support dentures present an alternative method of restoring patients with atrophic jaws. They dramatically broaden the spectrum of overdenture patients who can be successfully treated. These small diameter implants (1.8 mm-3.0 mm) differ from their full-sized counterparts in a number of significant ways. The configuration of the implant permits a more conservative placement protocol. No tissue flaps or tapping procedures are required, which results in fewer traumas

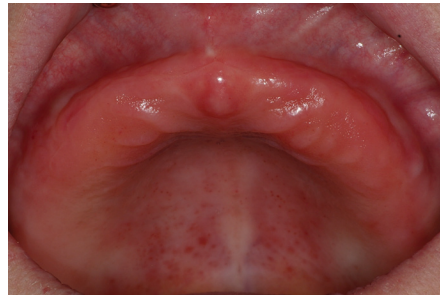


Figure 1: Preoperative retracted view of maxillary arch

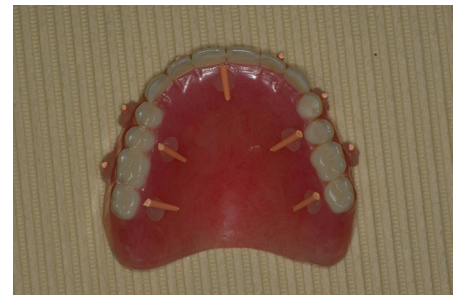

Figure 2: Denture with radiopaque markers

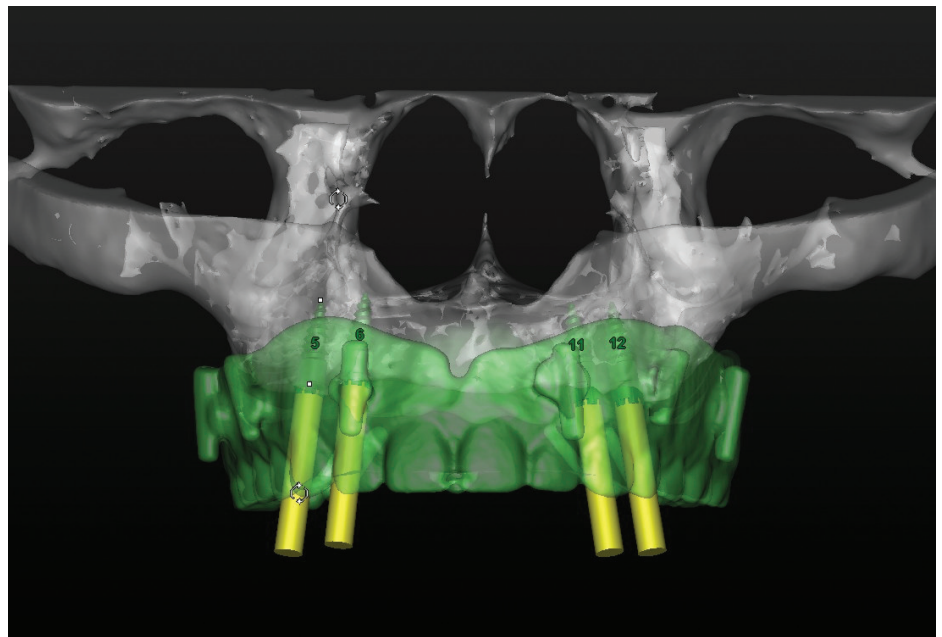


Figure 3: Virtual treatment plan from 3DDX

to both gingival tissue and bone. Their smaller size also permits placement in ridges that might not otherwise be suitable for full-sized implants.

Case history

A woman in her early 60s presented to our office frustrated with her upper complete denture that opposed a lower complete overdenture supported by five dental implants with corresponding Locator® (Zest) attachments. She complained that her upper denture was currently non-retentive, always moving around during eating. She was pleased with her lower

overdenture, so she requested a similar type of restoration for the upper arch.

Palpation and radiographic examination revealed a moderately narrowed maxillary ridge that would not allow adequate width for traditional-sized dental implants (Figure 1). Because of this, it was decided to get a CT scan to accurately detect the amount and quality of bone remaining in the maxilla.

Using a dual scan technique, the patient's denture was scanned individually as well as in the patient's mouth. It is important to note the denture had radiographic markers (gutta-percha points) placed on the facial and palatal aspects



Ara Nazarian, DDS, DICOI, maintains a private practice in Troy, Michigan with an emphasis on comprehensive and restorative care. He is a Diplomate in the International Congress of Oral Implantologists (ICOI). His articles have been published in many of today's popular dental publications. Dr. Nazarian is the director of the Reconstructive Dentistry Institute. He has conducted lectures and hands-on workshops on esthetic materials and dental implants throughout the United States, Europe, New Zealand, and Australia. Dr. Nazarian is also the creator of the DemoDent patient education model system. He can be reached at 248-457-0500 or at the Web site www.aranazariandds.com.

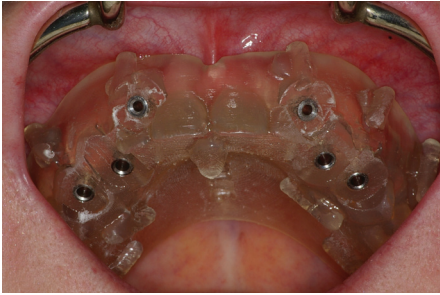


Figure 4: Pilot surgical guide



Figure 5: 1.6 mm pilot drill

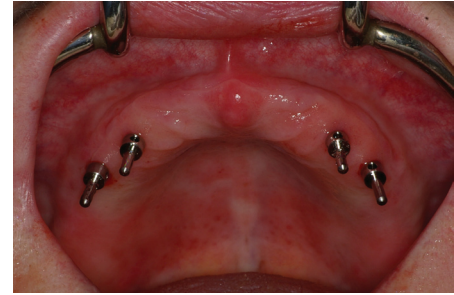

Figure 6: Paralleling pins



Figure 7: Zest's LODI implants



Figure 8: LODI implant ready for insertion

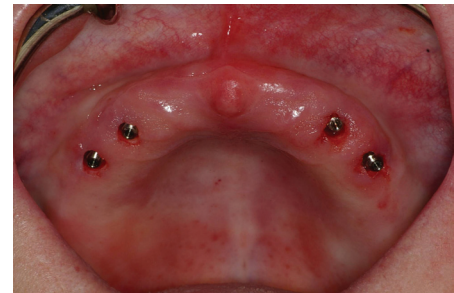

Figure 9: Placement of LODI implants



Figure 10: 2.5 mm gingival height Locator attachment

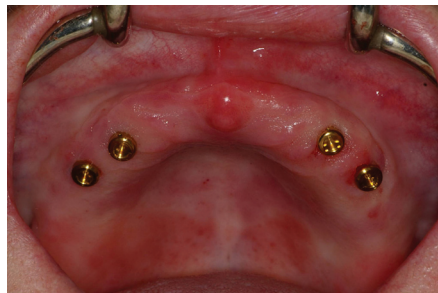

Figure 11: Locator attachments tightened onto implants

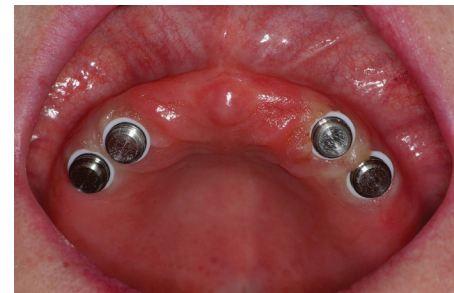

Figure 12: Locator caps with block out rings

of her existing denture held by sticky wax (Figure 2).

The DICOM file was then seamlessly uploaded to 3DDX.com (3D Diagnostics) for conversion and a treatment planning session using SimPlant (Materialise). With the assistance of the doctor on staff, we identified the most ideal areas for placement of the implants within the boundaries of the prosthesis (Figure 3). In order to stabilize her maxillary denture, four dental implants would be placed in the premaxilla area to aid in the retention of this prosthesis. Our selection consisted of four 2.9 mm x 10 mm Zest LODI (Locator Overdenture Dental Implants) dental implants. Once implant size and location were agreed upon, a surgical pilot guide was ordered by 3DDX and fabricated by SimPlant® (Materialise) (Figure 4).

Freestanding small diameter implants

with attachments like the Locator Overdenture System (Zest) used to retain overdentures provide numerous advantages, including enhanced esthetics, phonetics, ease of maintenance, low cost, and simplified hygiene for patients who don't have the bone for traditional-sized dental implants. It is important to remember that this type of prosthesis is primarily tissue-borne with the implants providing retention and stability. According to Misch's classification, this would be a RP5 restoration.

Utilizing the pilot surgical guide for alignment, a 1.6 mm pilot drill was placed into the sites and advanced to the full depth using a surgical motor (AEU-7000E, Aseptico) with generous amounts of cooled sterile water at a set speed of 1200rpm. Once the initial osteotomies were created, the surgical guide was removed. The pilot

drill was then reintroduced into the sites with a surgical stop ensuring adequate length was achieved (Figure 5).

Paralleling pins (Zest) were placed in the sites of the osteotomies (Figure 6), and an X-ray taken to check the angulations to ensure proper orientation among the implant sites. Once the osteotomies were completed, four (2.9 mm x 10 mm) LODI dental implants (Figure 7) were placed in the osteotomies using the implant latch driver (Figure 8) set at a speed of 50rpm with a placement torque at 35Ncm until increased torque was necessary. The ratchet wrench was then connected to the adapter, and the implants torqued to final depth reaching a torque level of 55Ncm (Figure 9). Since the final seating torque measured over 30Ncm, the implants were immediately loaded.

A 2.5 mm height Locator attachment

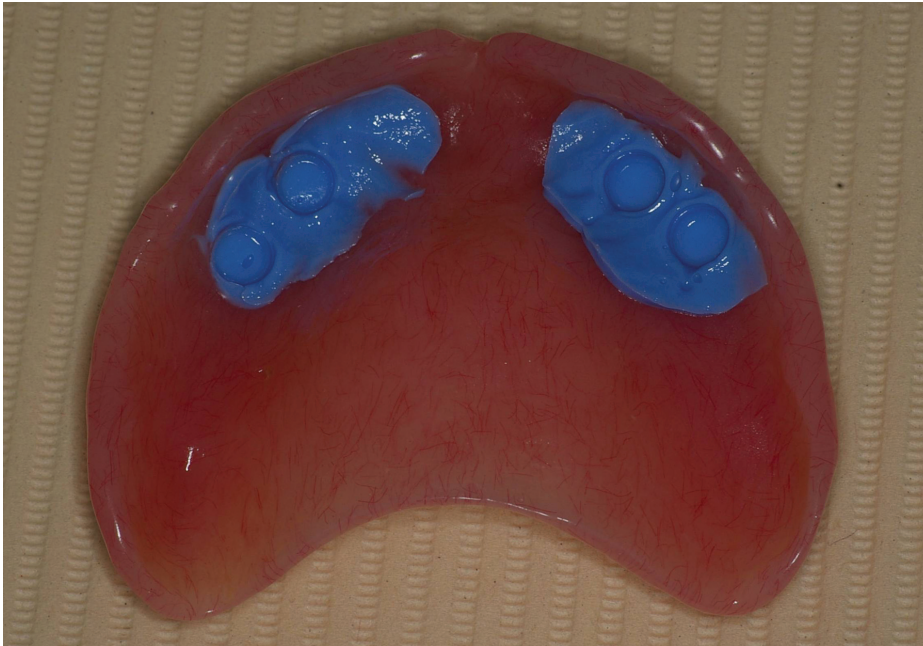


Figure 13: VOCO's fit test check

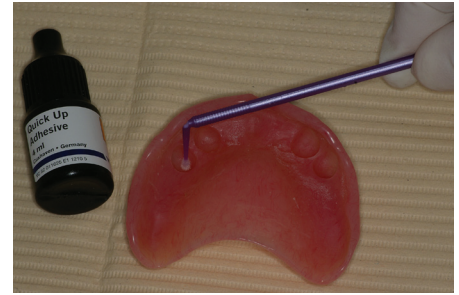

Figure 14: Placement of adhesive for pick-up material

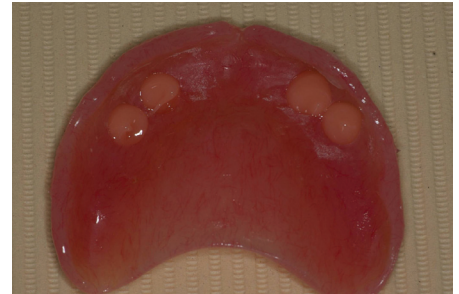


Figure 15: Placement of Quick Up into denture

was placed onto the implants (Figures 10 and 11) with a white block out spacer ring and Locator denture cap (Figure 12). Utilizing a marking stick (Dr. Thompson's Marking Sticks), we identified the areas in the denture that would require removal for the overdenture housings. Once relieved, Quick Up Test C&B silicone (VOCO America) was injected into the overdenture recesses. The overdenture was seated over the attachment caps and the Quick Up Test C&B (VOCO America) was allowed to set before the overdenture was removed. Any interference that was detected between the denture base and attachments was checked and eliminated (Figure 13).

Adhesive was added to the cleaned and dried recesses (Figure 14) that we created in the denture and filled with cold cure acrylic (Quick Up, VOCO America) [Figure 15]. Additionally, Quick Up material was also placed onto the Locator caps (Figure 16). The denture was then seated onto the implants and allowed to polymerize. Upon setting, the denture was relieved of any excess flash (Figure 17). The patient was very pleased with the fit, function and esthetics of the modified denture prosthesis. The Panorex X-ray of the implants depicted an ideal placement (Figure 18).

With the addition of small diameter implants such as the Locator Overdenture

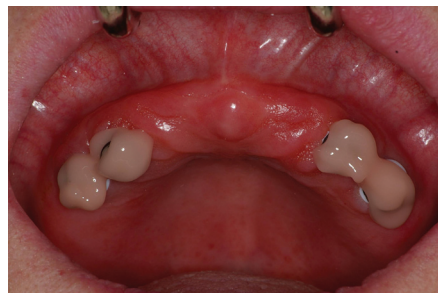

Figure 16: Placement of Quick Up onto Locator caps

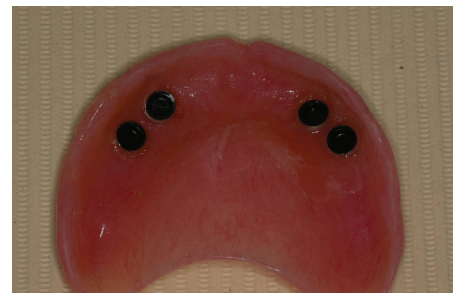

Figure 17: Denture with picked up housings

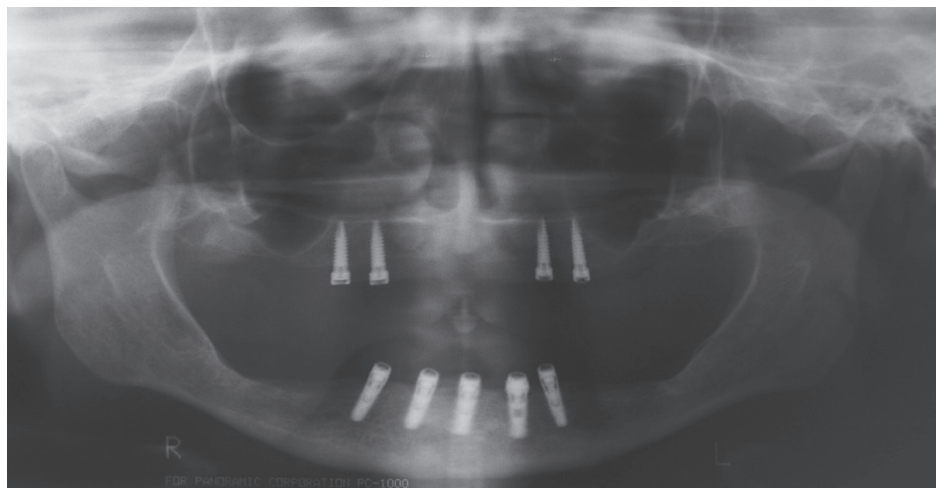


Figure 18: Final panorex

Implants, thin ridges can now benefit from denture stabilization with the huge benefit of the Locator (Zest) overdenture attachment system. Some of the advantages of the Locator (Zest) attachment system include a self-aligning feature, dual-retention, and

one of the lowest implant attachment profiles available. Most importantly, these small diameter implants give dentists and their patients an easy, less , and rapid way of solving many of the difficult problems that arise in with complete dentures. **IP**